

ADVANCES AND CURRENT PROGRESS OF LIVER SURGERY

Marek Krawczyk

Medical University of Warsaw, Poland

Keywords: liver anatomy, liver surgery, liver resection, liver ischemia

Contents

1. Introduction
 2. Terminology
 3. Liver resection
 - 3.1. Liver Resection Nomenclature
 - 3.2. New Diagnostic Possibilities
 - 3.3. Principles of Liver Resection
 - 3.3.1. Vascular Control
 - 3.3.2. New Surgical Devices
 4. Operative procedures
 - 4.1. Laparoscopic Technique
 - 4.2. Management of the Portal Hypertension
 5. Treatment of the most common liver lesions
 - 5.1. Benign Tumors
 - 5.1.1. Cysts
 - 5.1.2. Hemangioma
 - 5.1.3. Focal Nodular Hyperplasia
 - 5.1.4. Adenoma
 - 5.2. Malignant Tumors
 - 5.2.1. Hepatocellular Carcinoma
 - 5.2.2. Cholangiocarcinoma (Peripheral Type)
 - 5.2.3. Secondary Tumors
- Glossary
Bibliography
Biographical Sketch

Summary

Modern liver surgery started in the 1950s when Lortat-Jacob and his colleagues performed the first anatomical hemihepatectomy. At that time C. Couinaud described the modern anatomy of the liver. The next mile stone was the clarification of the ways to control bleeding during liver resection. The Pringle maneuver and total vascular occlusion helped surgeons to control the hemorrhage which earlier had been a major problem during liver operations.

Remarkable progress was made with new possibilities in the diagnostic area of liver diseases. A number of imaging modalities are now available to assess the hepatic parenchyma, vasculature, and biliary tree.

The out-dated cholecystography and intravenous cholangiography has been replaced by

modern sonography. Today, sonography is the initial study of choice for hepatobiliary disorders. It is relatively inexpensive, does not require ionizing radiation and can be used both at the bedside and intraoperative. Modern ultrasound examination shows not only the stones in the gallbladder but is also very helpful in analysis of liver lesions. The Doppler scan enables analysis of the arterial, portal and hepatic blood flow. Contrast agents have been introduced to enhance the accuracy of ultrasound; which includes a micro-bubble technique for very small lesion detection.

Nowadays new computed tomography is very accurate in defining hepatic anatomy with vascular and biliary tree reconstruction. It gives us detailed information about the architecture of the liver and three dimensional reconstructions. CT with intravenous contrast is an excellent way to identify and characterize hepatic masses.

Magnetic resonance imaging with cholangioMRI is another diagnostic device. MRI produces images in a number of planes and provides an excellent resolution between tissues containing differing amounts of fat and water.

CholangioMRI has developed our possibilities in diagnosis of biliary tree changes. It is an alternative method of diagnostic endoscopic cholangiopancreatography. The study in comparison with retrograde cholangiography is non invasive and provides very precise pictures.

A further option for liver imagery is positron emission tomography. Clinical applications include detection and staging of primary hepatic malignancies, evaluation of metastases, and differentiation of benign from malignant liver lesions.

Modern liver surgery depends also on new devices used during the operation. The liver surgeon has an accurate knowledge of liver anatomy and is equipped with new tools for liver resection. Old techniques such as finger fracture have been replaced by ultrasonic dissector, harmonic scalpel, and water jet. Today we speak about bloodless liver surgery and we do a termoresection exploiting the idea known from termoablation of liver tumor.

The new diagnostic possibilities, new tools for liver resection and modern knowledge of liver, allows surgeons to improve the results in the treatment of liver diseases. Benign tumors as cysts, hemangiomas, focal nodular hyperplasia, adenomas are recognized with the help of ultrasound, CT or MRI. The treatment strategy based on accuracy diagnosis helps us to recommend for surgery only symptomatic lesions.

Major progress has been observed in the diagnosis of hepatocellular carcinoma, cholangiocarcinoma as well as secondary tumors. Very rarely do we decide to conduct a biopsy. The diagnosis is grounded on less invasive imaging procedures. We know which group of patients with hepatocellular carcinoma can profit from surgery, how we should stage the tumors and in what time send the patients for liver transplantation. We must remember that the majority of patients with HCC suffer from cirrhosis and the liver resection is very limited.

Differentiation of peripheral cholangiocarcinoma is very difficult in regard to other types of adenocarcinoma. Also this lesion is an indication for liver surgery. The

problem is with early diagnosis because the tumor grows in the healthy liver.

Secondary tumors are the most common tumors in liver parenchyma. Cure resection is the choice of treatment of these group of patients. But synchronous colorectal liver metastasis in many patients is out of surgery. Only about 15 – 20% patients with metachronous liver metastasis can be resected. Present liver surgery gives new strategies for bilobar metastasis. The so called two step hepatectomy with portal vein embolization increases resectable rate. In general the survival time of patients with secondary tumors has increased and the mortality and morbidity after liver resection decreased.

1. Introduction

The oldest document describing the liver dates back to the Mesopotamian period. Stone inscriptions from this period indicate the year 3500 B.C. Sumerians and Acadians also had knowledge about some body organs including the liver. The liver was then considered as an organ of fate and priests described the livers of sacrificial animals with particular diligence. On the basis of the nature of the surface, the configuration, and the consistency of the organ prediction was made and seen as determining fate. In about 2000 B.C. priests made various interpretations for making divinations.

This sort of divination was also found in the Holy Bible. In the Old Testament it is said how important for life the liver is. The Egyptians, too, during the embalming of the kings handled the liver particularly cautiously. Plato believed that the liver was the seat of the organic soul. In Ancient Greece the legend of Prometheus indicated the regenerational possibilities of the liver because every day the eagle ate up Prometheus' liver only to be regenerated during the night. The first exact position of the liver was described by Herophilos of Chalcedon (334 – 280 B.C.). The next important data originates from Galen of Pergamon (129 – 199 AD), who created the medical and anatomical basis of the liver that remained unsurpassed until the 15th century.

The improved knowledge of liver anatomy resulted in further progress. In 1888 Rex and in 1898 Cantlie described the blood supplies to the two lobes of the liver. They also indicated the line of the division of the liver into two lobes.

The first liver resection with control of the blood supply to the resected lobe was performed by Walter Wendel in 1911. The first fully anatomical liver resection was performed in 1952 by Lortat-Jacob.

In 1954 Claude Couinaud made the full description of the segmental division of the liver corresponding to the portal, arterial and hepatic blood flow as well as biliary tree division.

In the 1950s Lin described “finger fracture”, the surgical technique of the division of the liver with the finger or blunt surgical instruments. This technique has remained popular until present times.

During recent years the technical instrumentation has been extended by new techniques

such as ultrasound dissection, laser application, water jet technology and others. Various types of coagulation and fibrin sealant technologies are used to cover the resected surface. This progress has diminished the mortality rate after liver resection from 15% to 2% - 3%.

2. Terminology

The modern term *liver anatomy* refers to the anatomy based on the liver division into 8 segments (Figure 1). Each segment is an autonomic unit of the liver. That means there is arterial blood supply, portal blood supply, outflow of blood through the hepatic vein and segmental hepatic duct by which bile flows out.

The term *liver resection* means that a part of the liver is removed. Liver resection can be anatomical and nonanatomical. We talk about anatomical liver resection when we perform a resection of one or more segments. If we perform a resection out of the segmental anatomy we call this procedure nonanatomical liver resection.

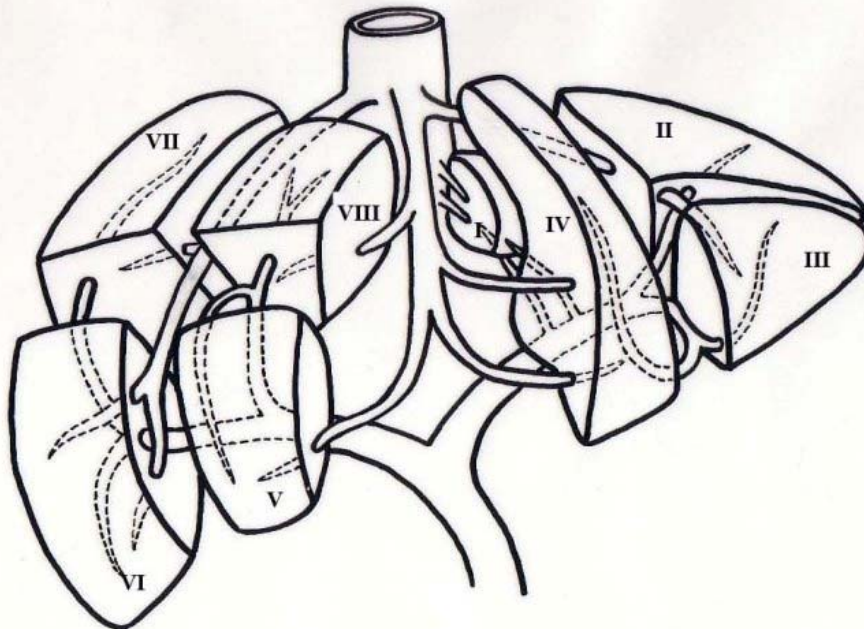


Figure 1. Schema of the anatomy of the liver – by C. Couinaud (1954)

The term *liver ischemia* indicates that the operation is performed with restriction of arterial and portal blood supply – temporal occlusion of the hepatic artery and portal vein. The term *total vascular exclusion* indicates a stop to blood inflow and blood outflow.

The term *hemihepatectomy* is used to describe the resection of segments I, II, III and IV – *left hemihepatectomy* or segments V, IV, VII and VIII – *right hemihepatectomy*. *Extended hemihepatectomy* means that liver resection comprises more than four segments e.g. the term *right extended hemihepatectomy* indicates that the resection includes segments IV, V, VI, VII and VIII.

3. Liver Resection

3.1. Liver Resection Nomenclature

The nomenclature of liver anatomy and resection was clarified in 2000. It was prepared after the International Hepato-Pancreato-Biliary Association Congress in Brisbane in Australia and published in *The Hepato-Pancreato-Biliary Surgery Journal*.

The term *right hemiliver* is equivalent to the *right liver* and *left hemiliver* is equivalent to the *left liver*. The border between the right liver and the left liver which separates the two hemilivers is a plane which runs from the gallbladder fossa to the fossa for the inferior vena cava and is called the midplane of the liver (Figure 2).

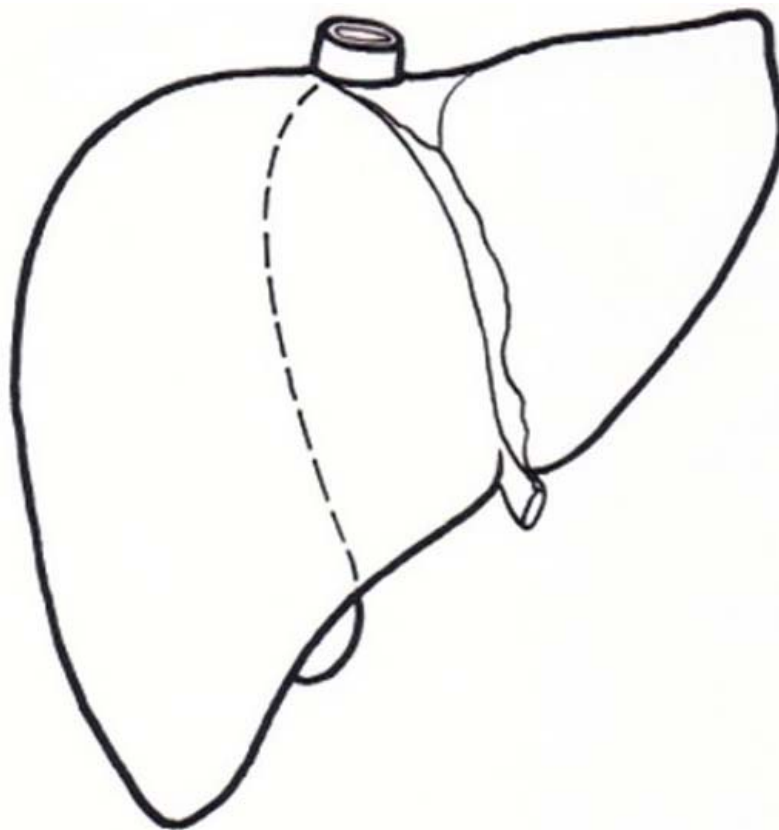


Figure 2. Schema of the midplane of the liver

The right liver consists of segments V, VI, VII, and VIII according to Couinaud nomenclature. The *right hepatectomy* or the *right hemihepatectomy* means that the surgeon removes segment V, VI, VII and VIII (Figure 3) and sometimes stipulates segment I. The *left hepatectomy* or the *left hemihepatectomy* means that the surgeon removes segment II, III and IV (Figure 4) and sometimes stipulates segment I.

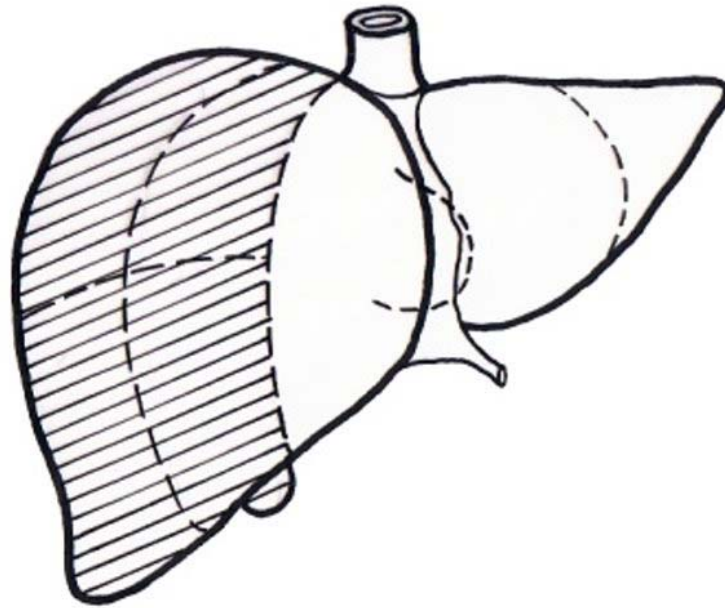


Figure 3. Schema of the right hepatectomy

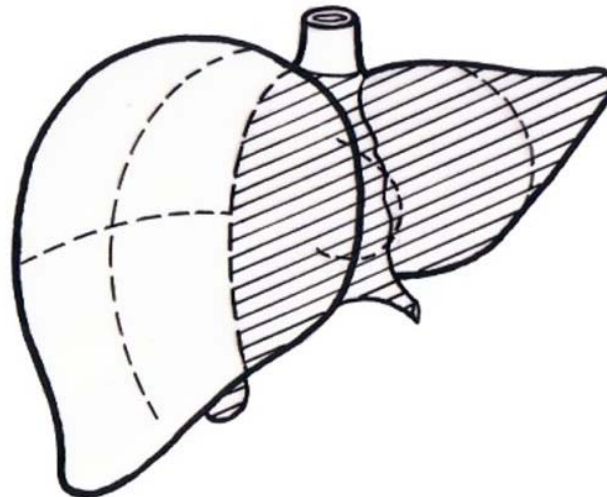


Figure 4. Schema of the left hepatectomy

In regard to bile ducts and the hepatic artery the liver is divided into four sections: right anterior section, right posterior section, left medial section and left lateral section. The right anterior section is comprised of Couinaud's segment V and VIII, right posterior section - segment VI and VII, left medial sector - segment IV and left lateral section - segment II and III. As regards the liver anatomy the term *right anterior sectionectomy* means that the surgeon removes segment V and VIII. The *right posterior sectionectomy* defines the removing of segments VI and VII. The *left medial sectionectomy* is the other attribute of the resection of segment IV. The *left lateral sectionectomy* means that segments II and III are removed. It is also called *bisegmentectomy II and III*.

During the resection we can remove only one segment – *segmentectomy* or two segments (II and III or V and VI) - *bisegmentectomy* (Figure 5).

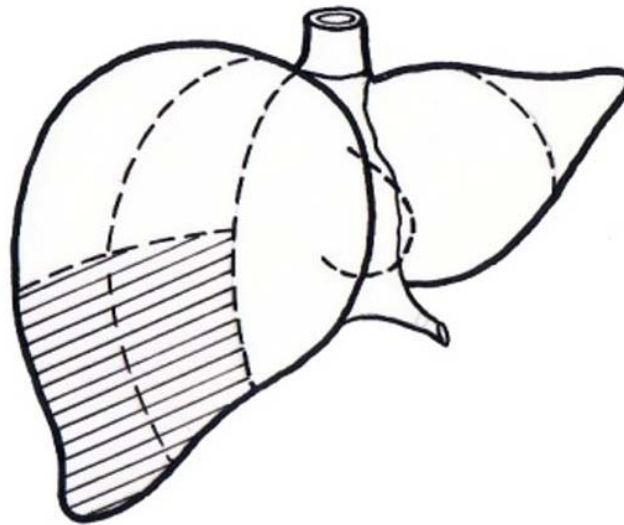


Figure 5. Schema of the bisegmentectomy

In American literature the term *right trisectionectomy* or *extended right hepatectomy* is sometimes used. During this operation we remove segments: IV, V, VI, VII and VIII. In special situations segments: I, IV, V, VI, VII and VIII may be resected. *Left trisectionectomy* or *extended left hepatectomy* means the resection of segments II, III, IV, V and VIII. Occasionally we can extend the left hemihepatectomy to segment I.

The term *right anterior sector* or *right paramedian sector* is based on portal vein division. It refers to segments V and VIII. The right anterior sector and right anterior section are synonyms. Surgical resection of this structure is called the *right anterior sectorectomy* or *right paramedian sectorectomy*. The right posterior sector or the right lateral sector comprises segments VI and VII and *right posterior sectorectomy* or *right lateral sectorectomy* means the removal of segments VI and VII. The right posterior sector and the right posterior section are synonyms. The left medial sector and the left paramedian sector concern segment III and IV respectively. *Left medial sectorectomy* or *bisegmentectomy* III and IV refer to the resection of segments III and IV. The left medial sector and the left medial section are not synonyms. The left lateral sector or the left posterior sector concern segment II, so *left lateral sectorectomy* or *left posterior sectorectomy* or *segmentectomy* II refer to resection of segment II. The left lateral sector and the left lateral section are not synonyms either. There is a difference between a small liver resection and a large one. The term *small liver resection* means that less than 2 segments are resected. The resection of 3 or more segments is called *large liver resection*.

-
-
-

TO ACCESS ALL THE 36 PAGES OF THIS CHAPTER,
Visit: <http://www.eolss.net/Eolss-sampleAllChapter.aspx>

Bibliography

- Amaral J.F., Chrostek C. (1995). Depth of thermal injury: ultrasonically activated scalpel vs. electrosurgery. *Surgical Endoscopy* **9**, 226. [Analysis of thermal injury during using ultrasonically scalpel versus electrosurgery]
- Ayav A., Navarra G., Habib N.A., Jiao L.R. (2005). New technique for liver resection using heat coagulative necrosis. *Annals of the Surgery* **242**, 751-751. [Description of benefits of a new technique for liver resection called termoresection]
- Baer H.U., Maddern G.J., Blumgart L.H. (1991). New water-jet dissector: initial experience in hepatic surgery. *British Journal of the Surgery* **78**, 502 – 503. [Description of initial experience in liver resection with water-jet device]
- Braunschweig R., Stern W., Dabidian A. (1993). Contrast enhanced colour Doppler studies of liver vessels. Abstract of Investigators meeting in Berlin. *Echocardiography*. November issue. [Initial information about contrast enhanced Doppler in liver investigations]
- Clavien P.A., Yadav S., Sindram D., Bentley R.C. (2000). Protective effects of ischemic preconditioning for liver resection performed under inflow occlusion in humans. *Annals of Surgery* **232**, 155 – 162 [Analysis of protection of liver injury during inflow occlusion by ischemic preconditioning]
- Colapinto R.F., Stronell R.D., Gildiner M. (1983). Formation of an intrahepatic portosystemic shunt using balloon dilatation catheter. Preliminary clinical experience. *American Journal of the Roentgenology* **140**, 709 – 714 [Preliminary clinical experience with the decompression of portal hypertension by intrahepatic portosystemic shunt].
- Couinaud C. (1954). Bases anatomiques des hépatectomies gauche et droite réglées, techniques qui en déroule. *Journal de Chirurgie (Paris)* **70**, 933 – 966. [Full description of the segmental division of the liver corresponding to the portal, arterial and hepatic blood flow as well as biliary tree division]
- Crafford C., Freckner P. (1939). New surgical treatment of varicose veins of the oesophagus. *Acta Otolaryngologica* **27**, 422. [Initial information about endoscopic treatment of varicose veins of the oesophagus]
- Gugenheim J., Mazza D., Kathpuda N. (1996). Laparoscopic resection of solid livers tumors. *British Journal of the Surgery* **83**, 334. [Preliminary clinical experience with laparoscopic resection of solid livers tumors]
- Heaney C., Jacobson A. (1975) Simplified control of upper abdominal haemorrhage from the vena cava. *Surgery* **78**, 138 -141. [Initial information about total vascular occlusion during liver resection]
- IHPBA Brisbane 2000 terminology of liver anatomy & resections (2000). *Journal of Hepatopancreatobiliary Association* **2**, 333-339 [Guidelines of the Committee of the International Hepato-Pancreato-Biliary Association for terminology of the liver anatomy and resection]
- Jaeck, D., Oussoultzoglou, E., Rosso, E., Greget, M. Weber, J.Chr. Bachellier, Ph. (2004). A Two-Stage Hepatectomy Procedure Combined With Portal Vein Embolization to Achieve Curative Resection for Initially Unresectable Multiple and Bilobar Colorectal Liver Metastases. *Annals of Surgery* **240**, 1037-1051. [Description of the results of the liver resection due to bilobar liver metastases with technique of two stage hepatectomy procedure with portal vein embolization]
- Jiao L.R., Navarra G., Weber J.C., Havlic R., Nicholls J.P., Habib N.A. (2006). Radio frequency assisted liver resection: the Habib's technique. *Advances in Experimental Medicine and Biology* **574**, 31-37. [Analysis of the advantage of bloodless liver surgery with Habib's technique]
- Lortat-Jacob J.L., Robert H.G., Henry L. (1952) Un cas d'hépatectomie droite réglée. *Mémoires Académie de Chirurgie* **78**, 244 – 251. [First description of anatomical right hepatectomy].
- Manfredi S., Lepage C., Hatem C., Coatmeur O., Faivre J., Bouvier A.-M. (2006). Epidemiology and management of liver metastases from colorectal cancer. *Annals of Surgery*, **244**, 254 – 259. [Analysis of the occur liver colorectal metastases and results of the treatment]
- Mazzaferro V., Regalia E., Doci R., (1996). Liver Transplantation for the treatment of small hepatocellular carcinoma in patients with cirrhosis. *New England Journal of Medicine* **334**, 693 – 699.

[Milan criteria of the cancer indication for liver transplantation].

Oussoultzoglou, E., Bachellier, P., Rosso, E., Scurtu, R., Lucescu, I., Greget, M., Jaeck, D. (2006). Right Portal Vein Embolization Before Right Hepatectomy for Unilobar Colorectal Liver Metastases Reduces the Intrahepatic Recurrence Rate. *Annals of Surgery* **244**, 71-79.[Analysis of the influence of the portal vein embolization on results of liver resection at unilobar liver metastases]

Pringle J.H. (1908). Notes on the arrest of hepatic haemorrhage due to trauma. *Annals of Surgery* **48**, 541 – 549 [First description of the occlusion of portal inflow to control hemorrhage after liver trauma].

Putnam C.W. (1983) Techniques of ultrasonic dissection in resection of the liver. *Surgery, Gynaecology and Obstetrics* **157**, 474 - 478.[Description of the ultrasonic dissection of the liver parenchyma during liver resection].

Stiegmann G.V., Goff J.S., Sun JH, Davis D, Bozdech J. (1989). Endoscopic variceal ligation: an alternative to sclerotherapy. *Gastrointestinal Endoscopy* **35**, 431 – 434.[Initial clinical experience in the treatment of oesophageal varices with endoscopic variceal ligation]

World Health Organisation Classification of tumors (2000) Pathology & Genetics. Tumors of the digestive system. Hamilton SR., Aaltonen LA (Ed.) IARC Press, Lyon.[New World Health Organisation classification of the liver tumors]

Biographical Sketch

Marek Krawczyk, M.D., Ph.D., Professor of Surgery, Medical University of Warsaw, was born in 1946 in Pruszków, Poland. A physician, graduated from Warsaw Medical University (Poland) in 1969. Scientific degrees: doctor of medicine (1975), associate professor (1987), and full professor (1995). Professional training and specialization in surgery gained at the Warsaw Medical University clinical centre, where he undertook his research and clinical assignment. Postgraduate research and professional training completed in Heidelberg University (Germany, 1978/79), Mannheim – Heidelberg University (Germany; 1989/90), University of Dundee (U.K.; 1991), Villejuif – Paris University (France; 1993/94) and Strasbourg University (France - 1995). Since 1998 Prof. Krawczyk has held the Chair of Surgery and heads the Department of General, Transplant and Liver Surgery at Warsaw Medical University and the Central University Hospital of Warsaw, respectively. From 2002 to 2008 he was Dean of the First Medical Faculty of Medical University of Warsaw. In 2008 he was appointed as Rector of the Medical University of Warsaw, Poland, and currently holds this position.

Prof. Marek Krawczyk is a member of several international and national scientific and professional associations (l'Academie Nationale de Chirurgie, France, International Hepato Pancreatic Biliary Association, Polish Society for Liver Studies, Polish Association of Surgeons, Polish Association of Gastroenterology, International Association of Surgeon and Gastroenterologists (Oncologists) etc.) and has published over 300 papers.